

Focal thinning of the cerebral cortex in multiple sclerosis

Michael Sailer,¹ Bruce Fischl,^{2,3} David Salat,¹ Claus Tempelmann,¹ Mircea Ariel Schönfeld,¹ Evelina Busa,² Nils Bodammer,¹ Hans-Jochen Heinze¹ and Anders Dale^{2,3}

¹Department of Neurology II, Otto-von-Guericke-University, Magdeburg, Germany, ²Nuclear Magnetic Resonance Center, Massachusetts General Hospital, Harvard Medical School, Charlestown, and ³MIT Artificial Intelligence Laboratory, MIT, Cambridge, MA, USA

Correspondence to: Michael Sailer, MD, Otto-von-Guericke-University Magdeburg, Leipzigerstr. 44 39120 Magdeburg, Germany
E-mail: michael.sailer@medizin.uni-magdeburg.de

Summary

Brain atrophy as determined by quantitative MRI can be used to characterize disease progression in multiple sclerosis. Many studies have addressed white matter (WM) alterations leading to atrophy, while changes of the cerebral cortex have been studied to a lesser extent. *In vivo*, the cerebral cortex has been difficult to study due to its complex structure and regional variability. Measurement of cerebral cortex thickness at different disease stages may provide new insights into grey matter (GM) pathology. In the present investigation, we evaluated *in vivo* cortical thickness and its relationship to disability, disease duration, WM T₂ hyper-intense and T₁ hypo-intense lesion volumes. High-resolution MRI brain scans were obtained in 20 patients with clinically definite multiple sclerosis and 15 age-matched normal subjects. A novel method of automated surface reconstruction yielded measurements of the cortical thickness for each subject's entire brain and computed cross-subject statistics based on the cortical anatomy. Statistical thickness difference maps were generated by performing *t*-tests between patient and control groups and individual thickness measures were submitted to analyses of variance to investigate the relationship between cortical thickness and clinical variables. The mean overall thickness of the cortical ribbon was

reduced in multiple sclerosis patients compared with controls [2.30 mm (SD 0.14) versus 2.48 mm (SD 0.11)], showing a significant main effect of group (controls versus patients). In patients, we found significant main effects for disability, disease duration, T₂ and T₁ lesion volumes. The visualization of statistical difference maps of the cortical GM thickness on inflated brains across the cortical surface revealed a distinct distribution of significant focal thinning of the cerebral cortex in addition to the diffuse cortical atrophy. Focal cortical thinning in frontal [2.37 mm (SD 0.17) versus 2.73 mm (SD 0.25)] and in temporal [2.65 mm (SD 0.15) versus 2.95 mm (SD 0.11)] brain regions was observed, even early in the course of the disease or in patients with mild disability. Patients with longstanding disease or severe disability, however, presented additionally with focal thinning of the motor cortex area [2.35 mm (SD 0.19) versus 2.74 mm (SD 0.15)]. We conclude that *in vivo* measurement of cortical thickness is feasible in patients suffering from multiple sclerosis. The data provide new insight into the cortical pathology in multiple sclerosis patients, revealing focal cortical thinning beside an overall reduction of the cortical thickness with disease progression.

Keywords: multiple sclerosis; cerebral cortex; atrophy; MRI

Abbreviations: EDSS = expanded disability status scale; GM = grey matter; ROI = region of interest; WM = white matter

Introduction

Axonal pathology and neuronal loss in multiple sclerosis have recently regained increasing attention. The macroscopic concomitant loss of brain tissue lends itself to quantification using neuroimaging (Miller *et al.*, 2002). Thus, cross-sectional MRI studies reported reduced cerebral, brainstem

and spinal volumes and enlarged ventricles compared with normal aged-matched subjects (Losseff *et al.*, 1996; Stevenson *et al.*, 1998; Rudick *et al.*, 1999; Brex *et al.*, 2001). Longitudinal studies revealed a faster rate of brain tissue loss in different clinical subtypes of multiple sclerosis

compared with controls (Simon *et al.*, 1999; Fox *et al.*, 2000; Ge *et al.*, 2000; Bakshi *et al.*, 2001b). Neurodegenerative pathology in multiple sclerosis may represent a major part in the development of permanent disability.

Diffuse atrophy in multiple sclerosis is a result of tissue reduction in both grey matter (GM) and white matter (WM); inflammation and oedema may also exhibit variable effects on tissue volumes. WM changes leading to neuronal loss have been studied extensively using a wide range of different magnetic resonance techniques (De Stefano *et al.*, 1998; Matthews *et al.*, 1998). However, very little is known about the contribution to atrophy of the cerebral cortex and GM outside the cortex in multiple sclerosis although recent investigations point towards a significant involvement (Chard *et al.*, 2002b; Cifelli *et al.*, 2003).

Although there have been a small number of pathological investigations of the cortex in multiple sclerosis, a direct involvement with lesions in the cortical ribbon is commonly recognized (Kidd *et al.*, 1999; Peterson *et al.*, 2001). It is not well understood how the cortex is affected and whether cortical changes are distributed diffusely or have predominant locations. So far, few neuroimaging studies in multiple sclerosis have assessed the cerebral cortex separately either by computing relative volume changes of GM compared with total intracranial volume (Chard *et al.*, 2002b), by measuring the concentration of N-acetyl-aspartate of cerebral cortex (Kapeller *et al.*, 2001; Chard *et al.*, 2002a; Sarchielli *et al.*, 2002) or showing abnormalities in magnetization transfer imaging studies in normal-appearing GM in primary progressive multiple sclerosis patients (Dehmeshki *et al.*, 2003). Detection and visualization of changes in absolute thickness of the cortical ribbon, which would allow study of the whole GM and its pattern of involvement, have so far not been performed in this disease. Accurately measuring cortical thickness may provide important information about the integrity of the cerebral cortex in multiple sclerosis and thus yield new insights into the pathophysiology of this disease.

Cortex thickness has been difficult to study, primarily because of its complex folding patterns, regional variability and lack of a reliable methodology to measure the cerebral cortex *in vivo*. In the present investigation, a novel method featuring automated surface reconstruction, transformation and high-resolution inter-subject alignment procedures were used. This method yields accurate measurements of the thickness of the cerebral cortex across the entire brain and facilitates the calculation of cross-subject statistics based on the cortical anatomy (Fischl and Dale, 2000). The purpose of this study is to: (i) evaluate *in vivo* the thickness of the cortical grey matter in multiple sclerosis patients; (ii) to assess whether there is a predominant location of cortical atrophy compared with an age-matched control group; and (iii) to describe its relationship with clinical features and T₂ hyper-intense and T₁ hypo-intense total lesion volumes.

Subjects and methods

Twenty patients with clinically definite multiple sclerosis (Poser *et al.*, 1983) (10 female and 10 male) were recruited. Eleven patients had a relapsing–remitting and nine a secondary progressive disease course as described by Lublin and Reingold (1996). The mean age of the patient group was 36.9 years (SD 7.5), with a mean disease duration of 6.1 years (SD 3.6) and a median EDSS (expanded disability status scale) (Kurtzke, 1983) score of 4.0 (range 1.0–7.0). Patients receiving steroid treatment within the last 30 days were excluded from the study. For different group comparisons, the multiple sclerosis patients were assigned either to three groups according to their disability measured by EDSS or to three groups in agreement with disease duration or to three age groups according to age. In addition, 15 healthy subjects from the same age group and approximately the same sex distribution (eight female and seven male subjects) were studied (mean age 36.5 years, SD 4.5). The characteristics of the groups are displayed in Table 1. All volunteers gave written informed consent to enter the study, which had been approved by the local institutional review board of The Otto-von-Guericke University, Magdeburg.

MRI

Imaging was performed in Magdeburg, Germany, with a neuro-optimized GE 1.5 T Signa Horizon LX scanner (General Electric, Milwaukee, WI, USA). A T₁-weighted 3D RF-spoiled Gradient Echo sequence [SPGR, 124 sagittal slices, 1.5 mm thickness, TR (repetition time) = 24 ms, TE (echo time) = 8 ms, flip angle = 30°, bandwidth = 10.4 kHz, in-plane resolution = 0.98 mm × 0.98 mm) was used to measure cortical thickness. Acquisition parameters were empirically optimized to increase grey/white matter image contrast. T₂- and proton density-weighted images were acquired using a conventional dual spin echo sequence (TR = 2800 ms, TE = 14 ms and 84 ms). T₁-weighted 2D images were obtained with a spin echo sequence (TR = 600 ms, TE = 20 ms). All 2D sequences were acquired as axial oblique contiguous 3 mm slices (256² image matrix, 24 cm field of view). The imaging protocol was identical for all subjects studied.

Measurement of cortical thickness

The 3D structural scan was used to construct models of each subject's cortical surface—an automated procedure involving segmentation of the cortical WM (Dale and Sereno, 1993; Dale *et al.*, 1999), tessellation of the grey/white matter junction, inflation of the folded surface tessellation patterns (Dale and Sereno 1993; Fischl *et al.*, 1999a) and automatic correction of topological defects in the resulting manifold (Fischl *et al.*, 2001). This surface was then used as the starting point for a deformable surface algorithm designed to find the grey/white and pial surfaces with sub-millimetre precision

Table 1 Group characteristics

	<i>n</i>	Female/ male		Age (years)	EDSS	Disease duration in years	T ₂ hyper- intensities (mm ³)	T ₁ hypo- intensities (mm ³)	Mean cortical thickness of total cortex (mm)
Patients	20	10/10	Median (range)	36.5 (23.0–56.0)	4.0 (1.0–7.0)	5.0 (1.0–13)	20.0 (3.1–48.3)	2.7 (0.1–10.2)	2.33 (1.99–2.48)
			Mean (SD)	36.9 (7.5)	4.1 (1.7)	6.1 (3.6)	22.0 (10.2)	3.5 (2.7)	2.30 (0.14)
Controls	15	8/7	Median (range)	36.0 (25.0–55.0)	n. a.	n. a.	n. a.	n. a.	2.43 (2.23–2.83)
			Mean (SD)	36.5 (4.5)	n. a.	n. a.	n. a.	n. a.	2.48 (0.11)
Groups									
Disability									
Mild	8	5/3	Median (range)	31.5 (23.0–44.0)	2.5 (1.0 – 3.0)	4.5 (1.0–22.0)	17.6 (9.9–24.4)	2.4 (0.9–6.8)	2.42 (2.32–2.48)
			Mean (SD)	31.5 (6.7)	2.4 (0.8)	4.8 (3.4)	17.4 (5.3)	2.6 (2.0)	2.41 (0.1)
Moderate	7	3/4	Median (range)	38.0 (28.0–50.0)	4.5 (4.0 – 5.0)	5.0 (1.0–22.0)	25.8 (5.7–48.3)	3.3 (0.1–10.2)	2.27 (2.06–2.47)
			Mean (SD)	39.1 (7.4)	4.5 (0.5)	4.8 (2.8)	24.5 (14.4)	3.6 (3.5)	2.29 (0.16)
Severe	5	2/3	Median (range)	39.0 (37.0–56.0)	6.5 (6.0 – 7.0)	10.0 (6.0–13.0)	23.7 (11.0–35.0)	3.8 (1.7–7.9)	2.19 (1.99–2.45)
			Mean (SD)	42.8 (7.4)	6.4 (0.4)	9.8 (2.8)	25.9 (8.3)	4.8 (3.1)	2.20 (0.16)
Disease duration									
Short	5	3/2	Median (range)	34.0 (26.0–45.0)	3.0 (1.0 – 4.0)	2.0 (1.0–3.0)	19.3 (3.1–33.0)	1.0 (0.1–3.8)	2.46 (2.06–2.48)
			Mean (SD)	34.6 (6.8)	2.7 (1.3)	2.0 (1.0)	20.0 (8.3)	1.8 (1.6)	2.38 (0.17)
Moderate	6	3/3	Median (range)	37.0 (23.0–44.0)	3.5 (3.0 – 6.0)	5.0 (4.0–5.0)	19.8 (5.7–48.3)	2.7 (0.3–10.2)	2.33 (2.15–2.48)
			Mean (SD)	35.6 (8.0)	3.7 (0.8)	4.7 (0.5)	21.2 (14.7)	4.0 (3.7)	2.32 (0.1)
Long	9	4/5	Median (range)	37.0 (25.0–56.0)	6.0 (1.0 – 7.0)	10.0 (6.0–13.0)	30.4 (9.8–45.8)	3.7 (1.4–7.9)	2.23 (1.99–2.45)
			Mean (SD)	39.0 (9.0)	5.1 (1.7)	9.3 (2.7)	28.4 (8.6)	4.2 (1.7)	2.26 (0.15)
T ₂ lesion volume									
Low	11	6/5	Median (range)	35.0 (23.0–45.0)	3.0 (1.0 – 6.5)	5.0 (1.0–13)	15.8 (5.6–20.7)	2.8 (0.3–6.8)	2.34 (1.99–2.48)
			Mean (SD)	34 (7.5)	3.5 (1.7)	5.9 (3.9)	14.8 (4.7)	2.9 (1.7)	2.29 (0.16)
High	9	4/5	Median (range)	38.0 (28.0–56.0)	5.0 (3.0 – 7.0)	6.0 (3.0–12.0)	30.5 (10.4–48.3)	3.8 (0.1–10.2)	2.33 (2.14–2.47)
			Mean (SD)	39.6 (9.2)	4.8 (1.4)	6.3 (3.7)	30.8 (8.0)	4.3 (3.6)	2.33 (0.13)
T ₁ lesion volume									
Low	10	5/5	Median (range)	36.5 (26.0–45.0)	3.5 (1.0 – 6.5)	5.0 (2.0–13.0)	18.3 (3.1–24.5)	1.3 (0.1–2.8)	2.35 (1.99–2.48)
			Mean (SD)	35.9 (6.2)	3.7 (1.6)	5.1 (2.7)	18.0 (8.0)	1.4 (0.9)	2.34 (0.15)
High	10	4/6	Median (range)	36.0 (23.0–56.0)	4.5 (1.0 – 7.0)	6.0 (1.0–10.0)	23.3 (10.9–48.3)	3.9 (2.6–10.2)	2.25 (2.06–2.48)
			Mean (SD)	37.9 (10.2)	4.5 (1.7)	7.2 (4.4)	25.4 (11.4)	5.5 (2.4)	2.28 (0.14)

n.a. = not applicable

(Fischl and Dale, 2000), as has been validated by comparison with manual measures made on post-mortem (Rosas *et al.*, 2002). This method uses both intensity and continuity information from the surfaces in the deformation procedure in order to interpolate surface locations for regions in which the MRI image is ambiguous (Fischl and Dale, 2000). For each subject, thickness of the cortical ribbon was computed on a uniform grid with 1 mm spacing across both cortical hemispheres, with the thickness being defined by the shortest distance between the grey/white and pial surface models. The thickness maps produced are not limited to the voxel resolution of the image and are thus sensitive to detecting sub-millimetre differences between groups (Fischl and Dale, 2000). Thickness measures were mapped to the inflated surface of each participant's brain reconstruction, allowing visualization of data across the entire cortical surface (i.e. gyri and sulci) without being obscured by cortical folding. Each subject's reconstructed brain was morphed to an average spherical surface representation that optimally aligned sulcal and gyral features across subjects (Fischl *et al.*, 1999a,b). This procedure provides accurate matching of morphologically homologous cortical locations among participants on the basis of each individual's anatomy while

minimizing metric distortion. This transform was used to map the thickness measurements into a common spherical coordinate system. The data were then smoothed on the surface tessellation using an iterative nearest-neighbour averaging procedure. Because this smoothing was restricted to the cortical surface, averaging data across sulci or outside GM was avoided.

Definition of regions of interest (ROIs) was performed by detection of contiguous regions of statistical significance as defined by the statistical difference maps. After checking for clustering of subcortical lesions to rule out artefactual segmentation effects, these areas of regional thinning were used to create ROIs on a standard brain, and then were mapped back to each individual participant using a high-dimensional spherical morphing procedure (Fischl *et al.*, 1999a) to find the homologous regions across subjects (Fig. 1).

Quantification of lesion volume

Lesion volume quantification was performed on the proton density weighted and on the T₁ weighted images using a semi-automated, local contour technique. All lesions were

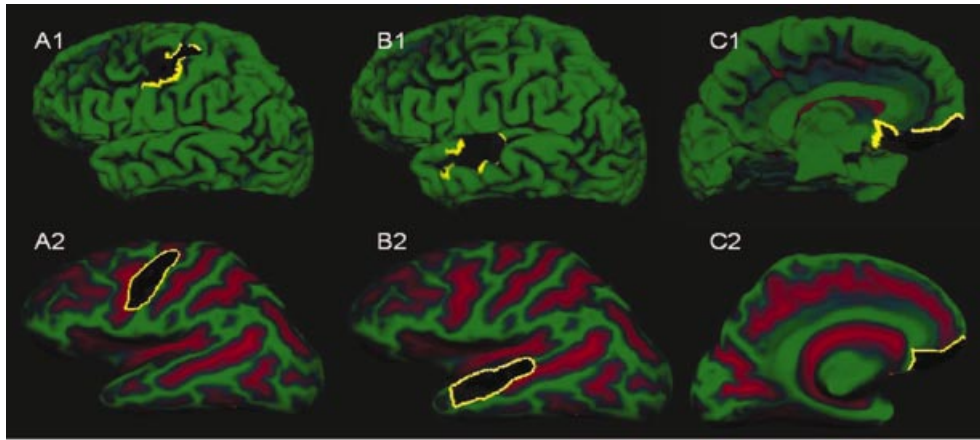


Fig. 1 ROIs (marked as black areas) demonstrated here on the left hemisphere were created on a standard inflated brain and then mapped back to each individual participant using a high-dimensional spherical morphing procedure to find the homologous regions across subjects. Displayed is a folded (A1, B1, C1) and a corresponding inflated view (A2, B2, C2). The yellow line represents the border of a ROI showing an impaired visualization due to cortical folding in A1, B1, C1. The right hemisphere was processed equally.

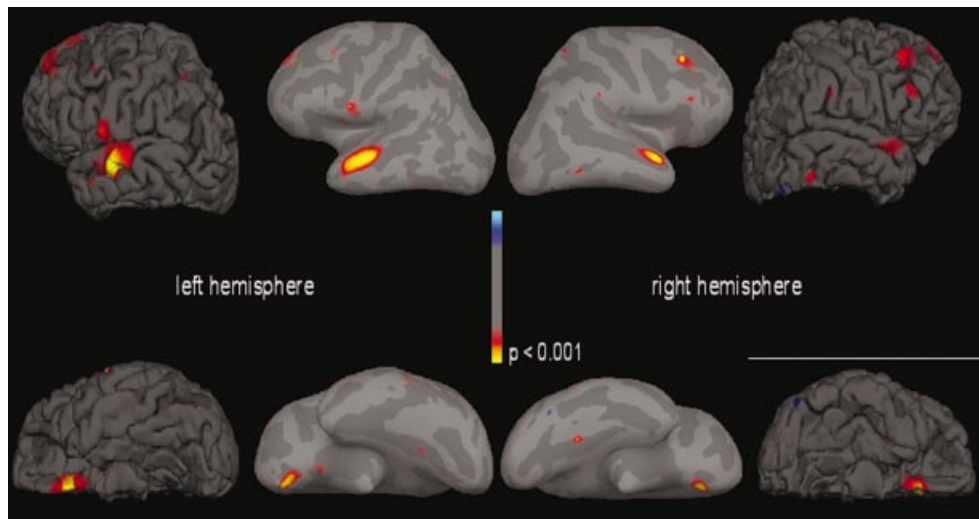


Fig. 2 Surface reconstruction with 3D rendering (folded view) and inflated brain. Dark grey areas correspond to sulci and lighter grey areas correspond to gyri. Statistical map: the average statistical map of 20 subjects with multiple sclerosis was compared with the average map of 15 control subjects. Cortical thinning is displayed on lateral (*top*) and medial (*bottom*) views of folded and inflated brains. Thinning across subjects was most significant in temporal and frontal brain regions. These maps demonstrate areas with highly significant reduction of cortical thickness in multiple sclerosis subjects, where statistical significance (colour scale) represents the dynamic range of thinning. Blue represents a significant thickening of the cortex. Full yellow corresponds to a statistical difference in cortical thickness with a P value of 0.001 that relates to at least up to 0.4 mm of cortical thinning.

marked on films prior the segmentation. T_1 lesions were identified as hypointense areas on the enhanced T_1 weighted scans and confirmed on a proton density weighted scan as lesions. The semi-quantitative lesion load measurement was performed using a highly reproducible (Molyneux *et al.*, 1998) threshold technique based upon the local environmental intensity of the lesion (DisplImage software package supplied by Dave Plummer, University College London, UK). The median T_2 lesion volume was 20.0 cm³ (range 3.1–48.3) and the median T_1 lesion volume amounted to 2.7 cm³

(range 0.1–10.2). Patients were assigned to two groups according T_2 and T_1 lesion loads (low $T_2 \leq 20$ cm³ and high $T_2 > 20$ cm³; low $T_1 \leq 3.0$ and high $T_1 > 3.0$ cm³).

Statistics

Maps were generated averaging across participants in the spherical space to construct both mean thickness difference maps [mean differences in cortical thickness between multiple sclerosis patients and controls at each point on the

Table 2 Mean cortical thickness in regions of interest according to clinical variables

	<i>n</i>	Mean cortical thickness (mm)			
		Total cortex	ROI		
			Frontal	Temporal	Motor cortex
Controls	15	2.48 (0.11)	2.73 (0.25)	2.95 (0.11)	2.74 (0.15)
Disability					
Mild	8	2.41 (0.11)	2.42 (0.16)	2.74 (0.11)	2.68 (0.23)
Moderate	6	2.29 (0.16)	2.37 (0.12)	2.63 (0.14)	2.40 (0.19)
Severe	6	2.20 (0.16)	2.26 (0.11)	2.57 (0.16)	2.35 (0.22)
Disease duration					
Short	5	2.38 (0.17)	2.41 (0.17)	2.71 (0.15)	2.70 (0.12)
Moderate	6	2.32 (0.10)	2.42 (0.10)	2.65 (0.16)	2.53 (0.17)
Long	9	2.26 (0.15)	2.32 (0.17)	2.63 (0.15)	2.33 (0.15)
T ₂ lesion volume					
Low	11	2.29 (0.16)	2.33 (0.15)	2.66 (0.19)	2.61 (0.30)
High	9	2.33 (0.13)	2.42 (0.14)	2.64 (0.10)	2.49 (0.19)
T ₁ lesion volume					
Low	10	2.34 (0.15)	2.66 (0.15)	2.81 (0.14)	2.69 (0.27)
High	10	2.28 (0.14)	2.39 (0.15)	2.66 (0.16)	2.38 (0.22)

Total cortex = mean cortical thickness. ROIs represent areas with significant thinning as indicated by the average statistical maps across subjects (see Fig. 1). Disability: mild = EDSS \leq 3 (n = 8); moderate = EDSS 3.5–5.5 (n = 7); severe = EDSS \geq 6 (n = 5). Disease duration: short = $<$ 3 years (n = 5); moderate = 3–5 years (n = 6); long = $>$ 5 years (n = 9). T₂ hyper-intense lesion volume: low = \leq 20 cm³ (n = 11); high $>$ 20 cm³ (n = 9). T₁ hypo-intense lesion volume: low = \leq 3 cm³ (n = 10); high $>$ 3 cm³ (n = 10)

reconstructed surface (data not shown)] and statistical thickness difference maps generated by performing *t*-tests between groups at each vertex using a random effects model across both cortical hemispheres. Regions showing significant thinning were defined as ROIs and the mean cortical thickness values in these ROIs were used for further analysis.

Individual thickness measures were submitted to ANOVAs (analyses of variance) to investigate the relationship between cortical thickness and clinical variables. Subsequent Bonferroni correction for multiple comparisons was applied for factors with more than two levels. In addition, correlations between cortical thickness and clinical or MRI data of the patients were calculated using nonparametric Spearman rank correlations coefficient (*r*) and corresponding two-tailed significance levels. *P* values $<$ 0.05 were considered significant. Data were processed with the statistical package SPSS© release 11.0.1 (SPSS Inc., Chicago, IL, USA).

Results

Multiple sclerosis patients versus normal controls

In this study, we compared the cortical thickness of 20 patients suffering from multiple sclerosis and 15 age-matched controls. Thickness measures were mapped to the inflated surface of each participant's brain reconstruction and statistical thickness difference maps were performed. The visualization of statistical thickness difference across the entire cortical surface (i.e. gyri and sulci) revealed a distinct

pattern of cortical atrophy in patients suffering from multiple sclerosis (Fig. 2).

The mean cortical thickness measured over the whole brain was reduced in multiple sclerosis patients compared with controls [2.30 mm (SD 0.14) and 2.48 mm (SD 0.11)]. This difference was substantiated by an ANOVA on the individual values with the factor group (patients versus controls) that revealed a significant main effect of group [$F(1,34) = 15.72$, $P < 0.001$].

Areas of significant cortical thinning were observed in different brain regions of the patients in comparison with normal controls (Fig. 2). In the frontal region (superior and medial frontal gyrus and sulcus of both hemispheres), the mean thickness was 2.37 mm (SD 0.17) and 2.73 mm (SD = 0.25) for multiple sclerosis and control groups, respectively. Significant focal cortical thinning was also present in the frontobasal regions near the frontal pole of the left and right hemisphere. For the temporal regions, mean cortical thickness was 2.65 mm (SD 0.15) in multiple sclerosis patients versus 2.95 mm (SD 0.11) in controls. There, the primary locations of cortical thinning were the superior and medial temporal gyrus and sulcus of both hemispheres (Table 2). Analysing all subjects (patients and controls), there was a main effect of age group (three levels) [$F(2,99) = 3.77$, $P = 0.028$], a main effect for group reflecting the differences between patients and controls [$F(1,104) = 80.57$, $P < 0.001$] as well as an interaction between age group and group [$F(1,104) = 11.88$, $P < 0.001$] (age group 1 \leq 34 years; age group 2 = 35–44 years and age

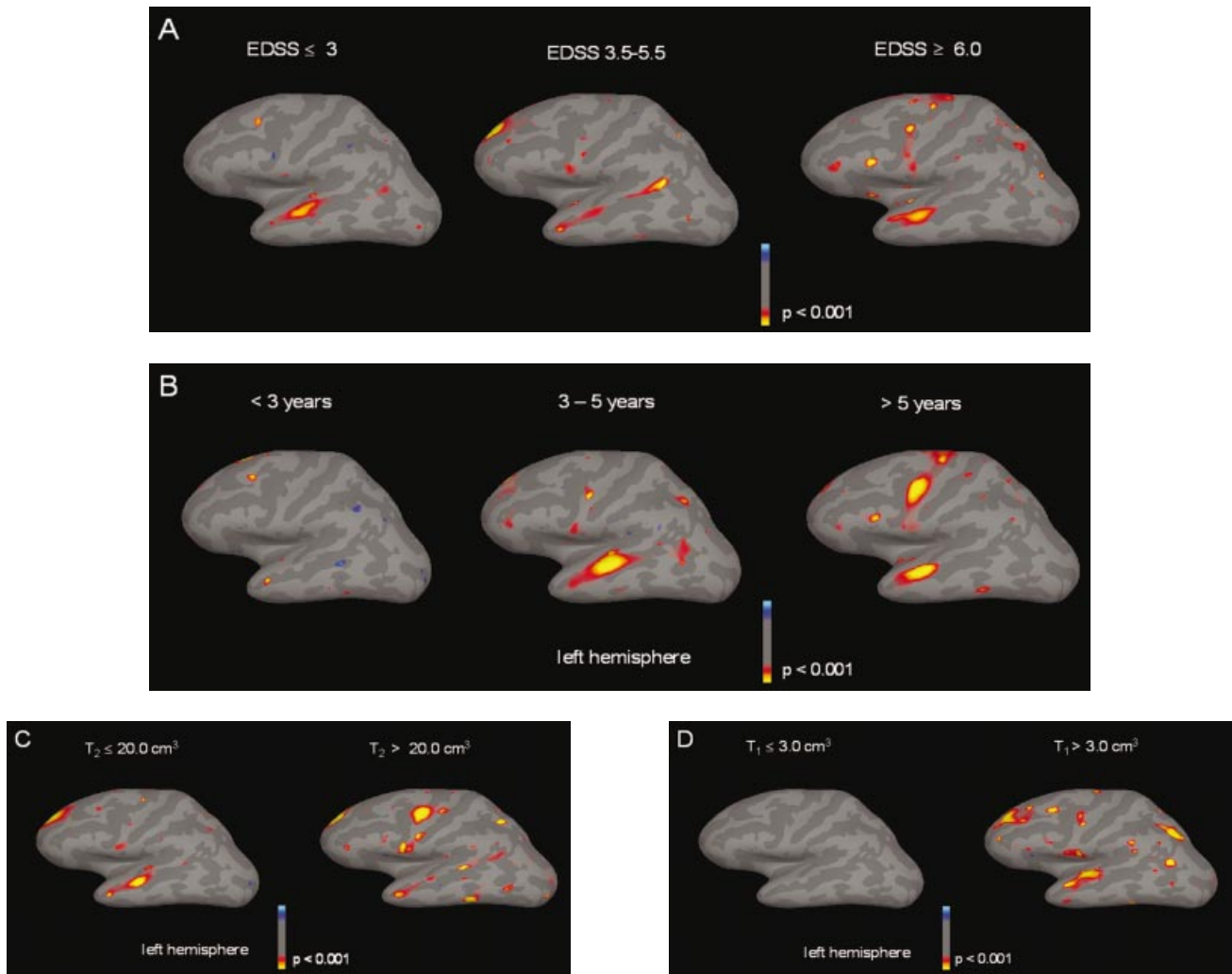


Fig. 3 The surface reconstruction demonstrates mean thickness differences of the cortex as statistical maps of multiple sclerosis subjects according to (A) disability, (B) disease duration, (C) T_2 hyper-intense and (D) T_1 hypo-intense lesion volumes in the white matter. Patient subgroups were compared with 15 control subjects. The statistical maps are overlaid on inflated brains. The colour scale shows the dynamic range of thinning. Blue represents a significant thickening of the cortex. Full yellow corresponds to a statistical difference in cortical thickness with a P value of 0.001 that relates to at least up to 0.4 mm of cortical thinning. (A) Average statistical map of eight multiple sclerosis subjects with a mild disability as measured on the expanded disability status scale ($EDSS \leq 3$). Seven multiple sclerosis subjects with moderate disability ($EDSS = 3.5-5.5$) and five multiple sclerosis subjects with severe disability ($EDSS \geq 6$) were compared with 15 age-matched control subjects. The surface reconstruction demonstrates predominant areas of focal cortical thinning differing with the degree of disability. Thinning of the frontal and temporal brain regions was observed in patients with mild and moderate disability. Patients with severe disability presented with additional thinning of the motor area. (B) Average statistical map of five multiple sclerosis subjects with short (<3 years), six multiple sclerosis subjects with moderate (3–5 years) and nine multiple sclerosis subjects with long disease duration (>5 years). With increasing duration of illness, statistical maps demonstrate progressive, focally located significant differences in mean cortical thickness. The reduction of cortical thickness in temporal lobes is already an early finding (<3 years), whereas in patients with longstanding disease, additional atrophy including the motor area is evident. (C) Average statistical map of 11 multiple sclerosis subjects with lower T_2 hyper-intense total lesion volumes ($\leq 20 \text{ cm}^3$) and nine multiple sclerosis subjects with high T_2 lesion volumes ($> 20 \text{ cm}^3$). Significant thinning across subjects was observed in both groups, again with predominant locations in frontal and temporal regions. Multiple sclerosis patients with high lesion load ($> 20 \text{ cm}^3$) revealed a significant thinning in motor area. (D) Average statistical map of 10 multiple sclerosis subjects with low T_1 hypo-intense total lesion volumes ($\leq 3 \text{ cm}^3$) and 10 multiple sclerosis subjects with high T_1 lesion volumes ($> 3 \text{ cm}^3$). There was a lack of significant difference in cortical thickness between patients with low T_1 lesion volumes and control subjects, whereas patients with high T_1 lesion volumes presented with atrophy of the cortex in the predominant locations including the motor cortex.

group 3 ≥ 45 years). Subsequent comparison between age groups showed, however, that there were no significant differences between the three age groups in controls. ANOVA across the patients only showed no significant

main effect for age group [$F(2,17) = 0.315$, $P > 0.05$], suggesting that the interaction between age group and group across all subjects was due to an age group effect in the controls group.

Cortical thickness and clinical variables

To investigate the relationship between cortical thickness and clinical parameters, patients' thickness values derived from the different ROIs were submitted to an ANOVA with the factors ROI location (frontal, temporal, motor), disability (mild = EDSS \leq 3, moderate = EDSS = 3–5.5, severe = EDSS \geq 6), disease duration (short = <3 years, moderate = 3–5 years, long = >5 years), T₁ lesion load (\leq 3.0 cm³, >3.0 cm³) and T₂ lesion load (\leq 20 cm³, >20 cm³). For mean thickness measures according to clinical variables, see Table 1.

Disability and cortical thickness

There was a highly significant main effect of disability [$F(2,59) = 19.82$, $P < 0.001$] as measured by the EDSS score on the cortical thickness values. *Post hoc* multiple comparisons showed significant differences between all disability levels. EDSS score correlated significantly with the mean over all cortical thickness ($r = -0.56$, $P = 0.011$). However, no significant interaction was found between disability and ROI location [$F(4,59) = 2.36$, $P = 0.11$].

In patients with mild disability (EDSS \leq 3), the statistical thickness difference maps showed significant focal cortical thinning in the distal part of the left and right superior temporal gyrus and sulcus (Fig. 3A). Similar differences with controls were also observed in patients with moderate disability (EDSS 3.5–5.5). There were, however, additional focal areas of cortical atrophy in the parietal and frontal medial gyri (Fig. 3A). Five patients with severe disability (defined here as EDSS \geq 6) demonstrated similar regional cortical atrophy in the temporal, parietal and frontal regions compared with those patients with moderate disability. In addition, small areas of significant atrophy were observed along the vicinity of the pre-motor and motor cortex (further referred to as motor cortex, Fig. 3A). EDSS correlated significantly ($r = -0.69$, $P = 0.001$) with the mean cortical thickness of the ROI that labelled the motor cortex.

Disease duration and cortical thickness

There was a highly significant main effect of disease duration [$F(2,59) = 11.51$, $P = 0.002$]. *Post hoc* multiple comparisons showed that the differences between all duration levels were significant. A trend could be observed for the interaction between disease duration and ROI location [$F(4,59) = 2.53$, $P = 0.09$]. To further elucidate the nature of this trend, statistical maps were calculated for the comparison patients versus controls for each disease duration level (Fig. 3B). Patients with disease duration of <3 years did not exhibit any significant focal cortical thinning compared with normal control subjects (Fig. 3B). In patients with disease duration up to 5 years, we observed significant focal atrophy that mainly involved the left and right temporal superior gyrus and sulcus, as well as the left and right frontal superior gyrus and sulcus.

The nine multiple sclerosis patients whose disease duration was >5 years exhibited pronounced focal atrophy beside the temporal and frontal areas, in the motor cortex of the left and right hemisphere. The disease duration correlated significantly with the mean cortical thickness of the ROI over the motor cortex from both hemispheres ($r = -0.53$, $P = 0.016$). The mean cortical thickness for the whole cortex and for the ROIs according to disease duration is shown in Table 2.

Lesion volumes and cortical thickness

Significant main effects on the cortical thickness were found for the T₁ [$F(1,59) = 6.17$, $P = 0.03$] as well as for the T₂ [$F(1,59) = 18.04$, $P = 0.001$] lesion volumes.

Significant interactions were found between the T₁ lesion volumes and disability [$F(1,59) = 30.01$, $P = 0.001$], disease duration [$F(1,59) = 6.29$, $P = 0.03$] and ROI location [$F(1,59) = 4.67$, $P = 0.03$]. The triple interactions between T₁ lesion volumes, disability and ROI location as well as between T₁ lesion volumes, disease duration and ROI location were significant [$F(2,58) = 8.28$, $P = 0.005$, and $F(2,58) = 4.15$, $P = 0.04$].

No significant interactions were found between the T₂ lesion volumes and all other clinical variables. However, a trend was found for the triple interaction between the T₂ lesion volumes, disability and ROI location ($F(2,58) = 3.86$, $P = 0.06$).

To further investigate this complicated pattern of results, statistical maps were calculated for the comparison patients versus controls for each T₁ and T₂ lesion volume level (Fig. 3C and D).

Multiple sclerosis patients with higher (>20 cm³) as well as lower (\leq 20 cm³) T₂ lesion volume showed reduced cortical thickness compared with controls. With the exception of the motor cortex, which was thinner in the high volume group in both hemispheres (Fig. 3C), T₂ lesion volume did not correlate significantly with the mean cortical thickness of the ROI labelled as motor cortex and T₂ lesion load did not correlate significantly with disability (EDSS).

Patients with high T₁ lesion volume (>3.0 cm³) showed a significant focal thinning of cortical sheets in temporal and frontal areas and along the motor cortex compared with controls. Those patients with low T₁ lesion volume (\leq 3.0 cm³), however, showed no differences to controls (Fig. 3D). T₁ lesion volume correlated significantly with the mean cortical thickness of the ROI labelled as motor cortex ($r = -0.54$, $P = 0.012$). No correlation between the total T₁ lesion volume and EDSS was found. The mean cortical thickness for the whole cortex and the ROIs according to lesion volumes is shown in Table 2.

Discussion

Our results establish a significant reduction of the cerebral cortex thickness in patients with multiple sclerosis. When we investigated the relationship between cortical thickness and

clinical variables, we found a highly significant association with disability, disease duration, T_2 and T_1 lesion volumes of cortical thickness values. The visualization of data across the entire cortical surface including both gyri and sulci—without being obscured by cortical folding—revealed a distinct distribution of focal cortical atrophy in multiple sclerosis patients. Highly significant focal atrophy was found predominantly in temporal, frontal and motor areas compared with normal controls. Significant cortical thinning in frontal and temporal areas occurred early in the disease course and was apparent in patients with mild disability or a shorter disease duration. A considerable commonality has to be contemplated between groups classified according to disease duration or disability when reviewing the pattern of the cortical involvement. Patients with severe disability or a longer course of the disease in addition exhibited significant thinning of the motor cortex. A trend could be observed for the interaction between disease duration and focal atrophy, whereas there was no significant interaction between EDSS and ROI location. The data presented reflect effects after correction for multiple comparisons. Although this approach might obscure discrete effects, it covers the robust properties.

Including the lesion volumes, significant interactions were found between T_1 lesion volume and EDSS, and T_1 lesion volume and ROIs. This was substantiated by further independent triple interactions on cortical thickness measures between T_1 lesion volumes, EDSS and disease duration and ROIs. T_2 lesion load, as a factor, exhibited a significant main effect on cortical thickness. However, there was no significant interaction between T_2 lesion volumes and all other clinical variables on the cortical measures. The triple interactions have to be regarded with caution because the sub-cohorts are small, thus rendering the results more vulnerable to effects of outliers. Nevertheless, this complex patterns of interactions suggests that disease duration could affect the spatial distribution of the cortical thinning. The disability is affected by cortical thinning in general, not primarily by its distribution. However, the significant interaction between T_1 lesion volume, location (ROIs) and disability across the cerebral cortex provides evidence that cortical thinning in distinct areas is closely related to progression of the disease and accumulation of lesions with a variable degree of axonal loss. This is illustrated by the statistical maps in Fig. 3.

We also found a main effect of age group for all subjects, but subsequent comparisons showed that there were no significant differences in cortical thickness between the three age groups. ANOVA across the patients only showed no significant main effect for age group. This suggests that the interaction between age group and group (controls/patients) across all subjects was due to an age group effect in the control group. Our populations, both patients and controls, have a relatively narrow age range and, moreover, the disease itself may exert effects which, influenced by disease severity, could mask an age effect in the patients group.

Thinning of the cortical ribbon corresponds to substantial pathological changes. Measuring the thickness of the cortex

may disclose information about the evolution of the disease as shown in neurodegenerative disorders such as Alzheimer's (Rusinek *et al.*, 1991; Jack *et al.*, 1997), Huntington's disease (Halliday *et al.*, 1998; Rosas *et al.*, 2002) and motor neuron disease (Kiernan and Hudson, 1994). In these disorders, the atrophy of the cerebral cortex has been attributed to progressive tissue shrinkage secondary to degeneration and neuronal loss. In general, the thickness of the cerebral cortex varies between 1 and 4.5 mm with a mean cortical thickness of ~2.5 mm (Brodman, 1909; Economo, 1929). Thus, a thinning of the mean cortical thickness of 0.18 mm in our study corresponds to a 7.2% loss of cortical thickness. A mean reduction in thickness of 0.21 mm of the motor ROI in patients with severe disability corresponds to a 11.3% thinning of the cortical thickness.

In multiple sclerosis, cortical atrophy could result from various mechanisms. First, a direct involvement of the cortex is recognized (Dawson, 1916) and has recently been described (Kidd *et al.*, 1999). The number of lesions is usually underestimated since they are rarely seen on conventional magnetic resonance sequences. Cortical and juxtacortical lesions may account for up to 24% of the total detected cerebral lesion load (Kidd *et al.*, 1999). The identified pathology in cortical lesions includes transected axons, dendrites and neuronal cell death (Peterson *et al.*, 2001). Based on the demyelinated areas, three types of cortical lesions were identified (Peterson *et al.*, 2001) and neuropathological data indicate that demyelination in the cortex is common in multiple sclerosis brains. The inflammatory activity within cortical lesion, as described in WM lesions (Trapp *et al.*, 1998), correlated with the extent of neuritic transections in cortical lesions. However, cortical lesions contained 13 times fewer CD3-positive lymphocytes and six times fewer CD68-positive microglia/macrophages than WM lesions (Peterson *et al.*, 2001), thus leaving the precise dynamics and incidence of cortical demyelination and neuronal loss unclear. In addition, different types of cortical lesions were identified based on the distribution of affected cortical layers and the neighbouring WM: (i) contiguous with subcortical WM matter lesions; (ii) small lesion confined to the cortex; and (iii) lesions extended from the pial surface to cortical layer 3 or 4. In contrast a topological distribution over the cortex or a predilection of cortical lesions as observed in WM remains elusive (Brownell and Hughes, 1962).

A second potential mechanism that could lead to focal cortical atrophy is evident from studies showing cortical changes after pyramidal lesioning (Tower, 1940; Kalil and Schneider, 1975; Brodal and Walberg, 1982). Following axonal transection, the distal segment undergoes Wallerian (anterograde) degeneration (Waller, 1850). In multiple sclerosis, degenerative changes in axons within the WM lesions and secondary degeneration of fibre tracts distal to the lesions have been documented (Matthews *et al.*, 1996; De Stefano *et al.*, 1998; Trapp *et al.*, 1998).

Data from animal studies after pyramidal tract lesioning provide convincing proof of proximal segments undergoing

retrograde axonal changes, i.e. showing evidence for the so-called slow dying back of the axon (Kalil and Schneider, 1975) with cell shrinkage and/or cell death (Al-Abdulla and Martin, 1998) in the cortical ribbon. Studies of retrograde cortical changes have varied in their observations of the extent of cell loss, ranging from severe shrinkage (Kalil and Schneider, 1975) to 80% cell loss (Tower, 1940; Brodal and Walberg, 1982) consequently leading to a substantial thinning of layers of the cortical ribbon.

In multiple sclerosis, the increase in lesion volume paralleling the disease course—particularly of lesions leading to a different degree of irreversible tissue loss such as the chronic T₁ hypo-intense lesions—may lead to neuronal damage with transection of axons and subsequent retrograde axonal damage of cortical neurons. Based on the distribution and the predominant site of WM lesions in the cerebrum (Brownell and Hughes, 1962; Narayanan *et al.*, 1997), a distinct pattern of the bulk of potentially damaging lesions evolves around the horns of the ventricles within fibre connections to the frontal, temporal and motor areas of the cortex. One may hypothesize that focal damage to the white matter and its connectivities in multiple sclerosis patients could be responsible for remote retrograde changes in appropriate regions of the cerebral cortex.

Our neuroimaging data show a significant thinning of the cerebral cortex in multiple sclerosis, supporting earlier neuropathological findings of tissue loss in the cerebral cortex. For the first time, we present absolute measurement of the cerebral cortex of multiple sclerosis patients *in vivo* with visualization of the thickness differences across the entire cortex. We found, beside an overall atrophy of the cortical ribbon, distinct cortical regions that exhibit significant focal atrophy. From the available evidence, the unequivocal origin of the focal atrophy of the cerebral cortex observed cannot be answered fully. We explicitly checked for clustering of subcortical or cortical lesions that could bias or influence the segmentation of the grey/white matter. In particular, the well-defined regions of cortical atrophy did not show any difference compared with other parts of the brain. We recognize that a direct mechanism such as cortical lesions [frequently seen in autopsy studies and rarely detected by MRI (Bakshi *et al.*, 2001a) and thus consequently underestimated] may contribute to general and focal cortical atrophy (Peterson *et al.*, 2001). The remote effects as discussed above (retrograde degeneration) leading to cortical changes are well documented and may develop as a consequence of destructive lesions located deeper in the white matter with a cortical distribution depending on the predominant sites of distant lesioning. Finally, we have to consider other neurodegenerative components developing independently of focal WM or GM lesions that may eventually play a role in the early development of atrophy in multiple sclerosis (Brex *et al.*, 2001). For clinical and monitoring purposes, the results have also demonstrated the utility of *in vivo* measurements of the cortical atrophy in disorders other than those associated with classical neurodegeneration. In multiple sclerosis, *in vivo*

accurate measurements of cortical thickness using advanced methods of MRI provide new insight into pathophysiology of this disease and may serve as an additional prospective marker of disease progression.

Acknowledgement

Support for this research was provided by The National Center for Research Resources (P41-RR14075 and IR01 RR16594-01A1).

References

- Al-Abdulla NA, Martin LJ. Apoptosis of retrogradely degenerating neurons occurs in association with the accumulation of perikaryal mitochondria and oxidative damage to the nucleus. *Am J Pathol* 1998; 153: 447–56.
- Bakshi R, Ariyaratana S, Benedict RHB, Jacobs L. Fluid-attenuated inversion recovery magnetic resonance imaging detects cortical and juxtacortical multiple sclerosis lesions. *Arch Neurol* 2001a; 58: 742–8.
- Bakshi R, Benedict RHB, Robert A, Jacobs L. Regional brain atrophy is associated with physical disability in multiple sclerosis: Semiquantitative magnetic resonance imaging and relationship to clinical findings. *J Neuroimaging* 2001b; 11: 129–36.
- Brex PA, Jenkins R, Fox NC, Crum WR, O’Riordan JI, Plant GT, et al. Detection of ventricular enlargement in patients at the earliest clinical stage of multiple sclerosis. *Neurology* 2001; 54: 1689–91.
- Brodal A, Walberg F. A re-evaluation of the question of ascending fibres in the pyramidal tract. *Brain Res* 1982; 232: 271–81.
- Brodman K. Vergleichende Lokalisationslehre der Grosshirnrinde in ihren Prinzipien dargestellt auf Grund des Zellenbaues. Leipzig: Barth; 1909.
- Brownell B, Hughes JT. The distribution of plaques in the cerebrum in multiple sclerosis. *J Neurol Neurosurg Psychiatry* 1962; 25: 315–20.
- Chard DT, Griffin CM, McLean MA, Kapeller P, Kapoor R, Thompson AJ, et al. Brain metabolite changes in cortical grey and normal-appearing white matter in clinically early relapsing–remitting multiple sclerosis. *Brain* 2002a; 125: 2342–52.
- Chard DT, Griffin CM, Parker GJ, Kapoor R, Thompson AJ, Miller DH. Brain atrophy in clinically early relapsing–remitting multiple sclerosis. *Brain* 2002b; 125: 327–37.
- Cifelli A, Arridge M, Jezzard P, Esiri MM, Palace J, Matthews PM. Thalamic neurodegeneration in multiple sclerosis. *Ann Neurol* 2002; 52: 650–3.
- Dale AM, Sereno MI. Improved localization of cortical activity by combining EEG and MEG with MRI cortical surface reconstruction: a linear approach. *J Cogn Neurosci* 1993; 5: 162–76.
- Dale AM, Fischl B, Sereno MI. Cortical surface-based analysis. I. Segmentation and surface reconstruction. *Neuroimage* 1999; 9: 179–94.
- Dawson JW. The histology of disseminated sclerosis. *Trans Roy Soc Edin* 1916; 50: 517–740.

- De Stefano N, Matthews PM, Fu L, Narayanan S, Stanley J, Francis GS, et al. Axonal damage correlates with disability in patients with relapsing-remitting multiple sclerosis. Results of a longitudinal magnetic resonance spectroscopy study. *Brain* 1998; 121: 1469–77.
- De Stefano N, Matthews PM, Filippi M, Agosta F, De Luca M, Bartolozzi ML, et al. Evidence of early cortical atrophy in MS: relevance to white matter changes and disability. *Neurology* 2003; 60: 1157–62.
- Dehmeshki J, Chard DT, Leary SM, Watt HC, Silver NC, Tofts PS, et al. The normal appearing grey matter in primary progressive multiple sclerosis. A magnetization transfer imaging study. *J Neurol* 2003; 250: 67–74.
- Economo C von. The cytoarchitectonics of the human cerebral cortex. London: Oxford University Press; 1929.
- Fischl B, Dale AM. Measuring the thickness of the human cerebral cortex from magnetic resonance images. *Proc Natl Acad Sci USA* 2000; 97: 11050–5.
- Fischl B, Sereno MI, Dale AM. Cortical surface-based analysis. II. Inflation, flattening, and a surface-based coordinate system. *Neuroimage* 1999a; 9: 195–207.
- Fischl B, Sereno M, Tootell RBH, Dale AM. High-resolution intersubject averaging and a coordinate system for the cortical surface. *Hum Brain Mapp* 1999b; 8: 272–84.
- Fischl B, Liu AK, Dale AM. Automated manifold surgery: constructing geometrically accurate and topologically correct models of the human cerebral cortex. *IEEE Trans Med Imaging* 2001; 20: 70–80.
- Fox NC, Jenkins R, Leary SM, Stevenson VL, Losseff NA, Crum WR, et al. Progressive cerebral atrophy in multiple sclerosis: a serial study using registered, volumetric MRI. *Neurology* 2000; 54: 807–12.
- Ge Y, Grossman RI, Udupa JK, Wei L, Mannon LJ, Polansky M, et al. Brain atrophy in relapsing-remitting multiple sclerosis and secondary progressive multiple sclerosis: Longitudinal quantitative analysis. *Radiology* 2000; 214: 665–70.
- Halliday GM, McRitchie DA, MacDonald V, Double KL, Trent RJ, McCusker E. Regional specificity of brain atrophy in Huntington's disease. *Exp Neurol* 1998; 154: 663–72.
- Jack CR Jr, Petersen RC, Xu YC, Waring SC, O'Brien PC, Tangalos EG, et al. Medial temporal atrophy on MRI in normal aging and very mild Alzheimer's disease. *Neurology* 1997; 49: 786–94.
- Kalil K, Schneider GE. Retrograde cortical and axonal changes following lesions of the pyramidal tract. *Brain Res* 1975; 89: 15–27.
- Kapeller P, McLean MA, Griffin CM, Chard D, Parker GJ, Barker GJ, et al. Preliminary evidence for neuronal damage in cortical grey matter and normal appearing white matter in short duration relapsing-remitting multiple sclerosis: A quantitative MR spectroscopic imaging study. *J Neurol* 2001; 248: 131–8.
- Kidd D, Barkhof F, McConnell R, Algra PR, Allen IV, Revesz T. Cortical lesions in multiple sclerosis. *Brain* 1999; 122: 17–26.
- Kiernan JA, Hudson AJ. Frontal lobe atrophy in motor neuron diseases. *Brain* 1994; 117: 745–57.
- Kurtzke JF. Rating neurologic impairment in multiple sclerosis: an expanded disability status scale (EDSS). *Neurology* 1983; 33: 1442–52.
- Losseff NA, Wang L, Lai HM, Yoo DS, Gawne-Cain ML, McDonald WI, et al. Progressive cerebral atrophy in multiple sclerosis. A serial MRI study. *Brain* 1996; 119: 2009–19.
- Lublin FD, Reingold SC. Defining the clinical course of multiple sclerosis: results of an international survey. National Multiple Sclerosis Society (USA) Advisory Committee on Clinical Trials of New Agents in Multiple Sclerosis. *Neurology* 1996; 46: 907–11.
- Matthews PM, Pioro E, Narayanan S, De Stefano N, Fu L, Francis G, et al. Assessment of lesion pathology in multiple sclerosis using quantitative MRI morphometry and magnetic resonance spectroscopy. *Brain* 1996; 119: 715–22.
- Matthews PM, De Stefano N, Narayanan S, Francis GS, Wolinsky JS, Antel JP, et al. Putting magnetic resonance spectroscopy studies in context: axonal damage and disability in multiple sclerosis. *Semin Neurol* 1998; 18: 327–36.
- Miller DH, Barkhof F, Frank JA, Parker GJM, Thompson AJ. Measurement of atrophy in multiple sclerosis: pathological basis, methodological aspects and clinical relevance. *Brain* 2002; 125: 1676–95.
- Molyneux PD, Tofts PS, Fletcher A, Gunn B, Robinson P, Gallagher H, et al. Precision and reliability for measurement of change in MRI lesion volume in multiple sclerosis: a comparison of two computer assisted techniques. *J Neurol Neurosurg Psychiatry* 1998; 65: 42–7.
- Narayanan S, Fu L, Pioro E, De Stefano N, Collins DL, Francis GS, et al. Imaging of axonal damage in multiple sclerosis: spatial distribution of magnetic resonance imaging lesions. *Ann Neurol* 1997; 41: 385–91.
- Peterson JW, Bo L, Mork S, Chang A, Trapp BD. Transected neurites, apoptotic neurons, and reduced inflammation in cortical multiple sclerosis lesions. *Ann Neurol* 2001; 50: 389–400.
- Poser CM, Paty DW, Scheinberg L, McDonald WI, Davis FA, Ebers GC, et al. New diagnostic criteria for multiple sclerosis: guidelines for research protocols. *Ann Neurol* 1983; 13: 227–31.
- Rosas HD, Liu AK, Hersch S, Glessner M, Ferrante RJ, Salat DH, et al. Regional and progressive thinning of the cortical ribbon in Huntington's disease. *Neurology* 2002; 58: 695–701.
- Rudick RA, Fisher E, Lee J-C, Simon J, Jacobs L, and the Multiple Sclerosis Collaborative Research Group. Use of the brain parenchymal fraction to measure whole brain atrophy in relapsing-remitting multiple sclerosis. *Neurology* 1999; 53: 1698–704.
- Rusinek H, de Leon MJ, George A, Stylopoulos LA, Chandra R, Smith G, et al. Alzheimer disease: measuring loss of cerebral grey matter with MR imaging. *Radiology* 1991; 178: 109–14.
- Sarchielli P, Presciutti O, Tarducci R, Gobbi G, Alberti A, Pelliccioli GP, et al. Localized (1)H magnetic resonance spectroscopy in mainly cortical grey matter of patients with multiple sclerosis. *J Neurol* 2002; 249: 902–10.

Simon JH, Jacobs LD, Campion MK, Rudick RA, Cookfair DL, Herndon RM, et al. A longitudinal study of brain atrophy in relapsing multiple sclerosis. *Neurology* 1999; 53: 139–48.

Stevenson VL, Leary SM, Losseff NA, Parker GJ, Barker GJ, Husmani Y, et al. Spinal cord atrophy and disability in multiple sclerosis: a longitudinal study. *Neurology* 1998; 51: 234–8.

Tower SS. Pyramidal lesion in the monkey. *Brain* 1940; 63: 36–90.

Trapp BD, Peterson J, Ransohoff RM, Rudick R, Mork S, Bo L.

Axonal transection in the lesions of multiple sclerosis. *New Engl J Med* 1998; 338: 278–85.

Waller AV. Experiments on the section of the glosso-pharyngeal and hypoglossal nerves of the frog, and observations of the alterations produced thereby in the structure of their primitive fibres. *Phil Trans R Soc Lond* 1850; 140: 423–9.

Received October 24, 2002. Revised February 24, 2003.

Second revision March 27, 2003. Accepted March 28, 2003