


Provided for non-commercial research and education use.  
Not for reproduction, distribution or commercial use.



This article appeared in a journal published by Elsevier. The attached copy is furnished to the author for internal non-commercial research and education use, including for instruction at the authors institution and sharing with colleagues.

Other uses, including reproduction and distribution, or selling or licensing copies, or posting to personal, institutional or third party websites are prohibited.

In most cases authors are permitted to post their version of the article (e.g. in Word or Tex form) to their personal website or institutional repository. Authors requiring further information regarding Elsevier's archiving and manuscript policies are encouraged to visit:

<http://www.elsevier.com/copyright>



Contents lists available at ScienceDirect

## Schizophrenia Research

journal homepage: [www.elsevier.com/locate/schres](http://www.elsevier.com/locate/schres)

## Gray matter volume reduction in rostral middle frontal gyrus in patients with chronic schizophrenia

Z. Kikinis<sup>a,\*</sup>, J.H. Fallon<sup>b</sup>, M. Niznikiewicz<sup>c</sup>, P. Nestor<sup>c,d</sup>, C. Davidson<sup>a</sup>, L. Bobrow<sup>a</sup>, P.E. Pelavin<sup>a</sup>, B. Fischl<sup>e,g</sup>, A. Yendiki<sup>e</sup>, R.W. McCarley<sup>c</sup>, R. Kikinis<sup>f</sup>, M. Kubicki<sup>a,c</sup>, M.E. Shenton<sup>a,c,f</sup>

<sup>a</sup> Psychiatry Neuroimaging Laboratory, Department of Psychiatry, Brigham and Women's Hospital, Harvard Medical School, Boston, MA, USA

<sup>b</sup> Department of Psychiatry and Human Behavior, University of California, Irvine, CA, USA

<sup>c</sup> Clinical Neuroscience Division, Laboratory of Neuroscience, Department of Psychiatry, VA Boston Healthcare System, Harvard Medical School Brockton, MA, USA

<sup>d</sup> Department of Psychology, University of Massachusetts, Boston, MA, USA

<sup>e</sup> Martinos Center for Biomedical Imaging, Massachusetts General Hospital, Harvard Medical School, Charlestown, MA, USA

<sup>f</sup> Surgical Planning Laboratory, Department of Radiology, Brigham and Women's Hospital, Harvard Medical School, Boston, MA, USA

<sup>g</sup> MIT CSAIL/HST, Cambridge, MA, USA

### ARTICLE INFO

#### Article history:

Received 6 April 2010

Received in revised form 24 July 2010

Accepted 26 July 2010

Available online 6 September 2010

#### Keywords:

Schizophrenia

Magnetic resonance imaging

Middle frontal gyrus

Dorsal lateral prefrontal cortex

Working memory

### ABSTRACT

The dorsolateral prefrontal cortex (DLPFC) is a brain region that has figured prominently in studies of schizophrenia and working memory, yet the exact neuroanatomical localization of this brain region remains to be defined. DLPFC primarily involves the superior frontal gyrus and middle frontal gyrus (MFG). The latter, however is not a single neuroanatomical entity but instead is comprised of rostral (anterior, middle, and posterior) and caudal regions. In this study we used structural MRI to develop a method for parcellating MFG into its component parts. We focused on this region of DLPFC because it includes BA46, a region involved in working memory. We evaluated volume differences in MFG in 20 patients with chronic schizophrenia and 20 healthy controls. Mid-rostral MFG (MR-MFG) was delineated within the rostral MFG using anterior and posterior neuroanatomical landmarks derived from cytoarchitectonic definitions of BA46. Gray matter volumes of MR-MFG were then compared between groups, and a significant reduction in gray matter volume was observed ( $p < 0.008$ ), but not in other areas of MFG (i.e., anterior or posterior rostral MFG, or caudal regions of MFG). Our results demonstrate that volumetric alterations in MFG gray matter are localized exclusively to MR-MFG. 3D reconstructions of the cortical surface made it possible to follow MFG into its anterior part, where other approaches have failed. This method of parcellation offers a more precise way of measuring MR-MFG that will likely be important in further documentation of DLPFC anomalies in schizophrenia.

© 2010 Elsevier B.V. All rights reserved.

### 1. Introduction

The dorsolateral prefrontal cortex (DLPFC) has figured prominently as abnormal in schizophrenia. [Weinberger et al.](#)

(1986) performed a now classic study implicating DLPFC in the working memory impairments observed in patients with schizophrenia. However, while the fMRI signal was attributed in this study to the site of working memory in DLPFC, the anatomical location of this activation pattern in the prefrontal cortex was not entirely clear, nor is it clear today.

An alternative and successful approach to localizing the site of working memory in DLPFC comes from work on nonhuman primates, where neurons in Brodmann area (BA) 46 and 9 exhibit persistent activity during working memory

\* Corresponding author. Psychiatry Neuroimaging Laboratory, Department of Psychiatry, Brigham and Women's Hospital, 1249 Boylston Street, 3rd Floor, Boston, MA, 02215, USA. Tel.: +1 617 525 6116; fax: +1 617 525 6150.

E-mail address: [zora@bwh.harvard.edu](mailto:zora@bwh.harvard.edu) (Z. Kikinis).

tasks (Goldman-Rakic, 1987). BA46 and BA9 also play an important role in working memory in humans (Petrides et al., 1993), and patients with schizophrenia show deficits in physiological activation especially in the BA 46 (Cannon et al., 2005; Perlstein et al., 2001). BA46 is, however, difficult to localize with neuroimaging methods because neuroimaging methods tend to use gyrification pattern as a reference system, and BA46, defined based on cytoarchitectonic findings on post-mortem brains, does not follow the gyrification pattern. Brodmann originally mapped one human brain into various cytoarchitectonic areas (Brodmann, 1909). Later, the mapping of area 46 was done on five human brains (Rajkowska and Goldman-Rakic, 1995) (Fig. 1B) and was found to have major regions of overlap located between coronal Talairach coordinates +50 and +29 in the AP plane (Fig. 1C). In comparison to Brodmann's definition, area 46 is more rostral and is of smaller extension. In morphometric nomenclature, the region of BA46 is a part of the middle frontal gyrus (MFG) (Rajkowska and Goldman-Rakic, 1995).

Two morphometric studies have explored BA46 in human subjects. The localization of BA46 is difficult to confirm because of the high variability of the gyral and sulcal patterns in individual subjects (Bartley et al., 1997; Noga et al., 1996) and because Brodmann areas do not always follow gyral patterns. Thus presently it is impossible to exactly determine the borders of BA46 in living subjects. Al-Hakim and co-workers nonetheless developed semi-automated rules to define an "average" BA46 in the MFG to be used in structural and functional imaging studies in living human subjects (Al-Hakim et al., 2006).

The second study, performed by Zuffante et al. (2001), attempted to delineate the region of BA46 in schizophrenia subjects. These investigators were able to draw on coronal slices between the Talairach coordinates  $y = 32$  and  $y = 45$ , but experienced technical difficulties between Talairach coordinates  $y = 45$  and  $y = 50$ , and for this reason did not include this part. The problems encountered by Zuffante and colleagues are not surprising. The complexity and variation of the gyrification pattern of the cortex in the rostral part of MFG

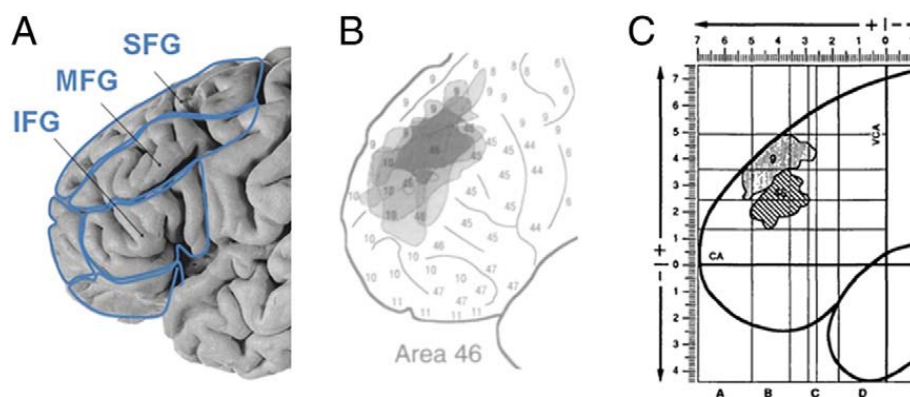
makes manual drawings in a 2-dimensional (2D) view very challenging.

A promising approach to delineate the prefrontal cortex is based on 3D-reconstructions of the brain's surface. Previously, 3D brain surface reconstruction was used as a visual guide to manually draw the ROIs of the prefrontal areas (Buchanan et al., 1998; Wible et al., 1997). In the current study, we used FreeSurfer software (<http://surfer.nmr.mgh.harvard.edu/>) to create a 3D reconstruction of the white matter surface. This software also automatically parcellates the brain into subregions, with the MFG delineated into rostral and caudal parts with high accuracy (Desikan et al., 2006). The caudal part of the MFG corresponds to the premotor area, while the rostral portion encapsulates a number of Brodmann areas, including BA46 (personal communication with Rahul Desikan). In addition, FreeSurfer has a tool that cuts brain regions along the coronal plane, which makes it possible to focus still further on the rostral part of the MFG by using the anterior and posterior boundaries as suggested by the cytoarchitectonic studies. For the purposes of this study, we more narrowly delineated FreeSurfer based parcellations of the rostral MFG in order to depict BA46 and we refer to this region as "mid-rostral middle frontal gyrus" (MR-MFG).

## 2. Methods

### 2.1. Subjects

Twenty male patients with chronic schizophrenia were recruited from the VA Boston Healthcare System, Brockton Division and were diagnosed with schizophrenia by trained raters using DSM-IV criteria, based on information from the Structured Clinical Interview for DSM-III-R (Spitzer et al., 1990b) and from medical records. Twenty male normal control subjects were recruited through newspaper advertisements and screened using the Structured Clinical Interview (SCID Non-Patient Edition) (Spitzer et al., 1990a) by the same trained interviewers who evaluated the patients. No control subjects had an Axis-I psychiatric disorder or a first-



**Fig. 1.** Definitions of prefrontal cortex and BA46. Panel A: The frontal lobe is divided into superior frontal gyrus (SFG), middle frontal gyrus (MFG) and inferior frontal gyrus (IFG) based on the gyrification pattern of the brain. Panel B: Superimposition of five reconstructions of BA46 displays the variation (in gray) and the common zone (in black). Reproduced from (Rajkowska and Goldman-Rakic, 1995) with permission of Oxford University Press. Panel C: Definition of BA46 (striped area), as the overlap region of individual extension of BA46 mapped on five postmortem human brains. The overlay BA46 is located between the +5 cm and +2.9 cm coordinates that translate into coronal Talairach coordinates +50 and +29. Reproduced from (Rajkowska and Goldman-Rakic, 1995) with permission of Oxford University Press.

degree relative with an Axis-I psychiatric disorder. Control subjects were group-matched to patients on age, sex, handedness, and parental socioeconomic status (PSES).

The inclusion criteria for all subjects were age between 18 and 55 years, no history of neurologic illness or major head trauma, no electroconvulsive therapy, no alcohol or drug dependence in the last 5 years, and no significant alcohol or drug abuse within the last year.

Premorbid IQ was assessed using the WRAT3 (Wide Range Achievement Test 3, scaled score) (Wilkinson, 1993) and current IQ was assessed using the WAIS-III (Wechsler Adult Intelligence Scale—3rd Edition) (Wechsler, 1997). The WRAT3 is a brief achievement test measuring reading recognition, spelling, and arithmetic computation. The test decodes skills acquired before the onset of the disease and these skills remain preserved during the disease (Dalby 1986). In contrast, the WAIS-III scale measures current adult and adolescent intelligence. The WAIS-III verbal IQ test combines verbal comprehension and working memory, and the WAIS-III performance IQ test includes perceptual organization and processing speed. The patients and the control subjects were administered both neuropsychological tests, the WRAT3 and the WAIS-III, to characterize intellectual abilities in the patient group (Weickert et al., 2000).

This study was approved by the VA Boston Healthcare System, Harvard Medical School, and Brigham and Women's Hospital Institutional Review Boards. Written informed consent was obtained from all subjects prior to study participation.

## 2.2. MRI acquisition, image processing and automated parcellation

### 2.2.1. MRI acquisition

MR images were acquired on a 3-Tesla whole body MRI EchoSpeed system General Electric scanner (GE Medical Systems, Milwaukee) at Brigham and Women's Hospital. An eight channel coil was used in order to perform parallel imaging using ASSET (Array Spatial Sensitivity Encoding techniques, GE) with a SENSE-factor (acceleration) of 2. The structural MRI acquisition protocol included the following pulse sequence and parameters: contiguous inversion-prepared spoiled gradient-recalled acquisition (fastSPGR), TR = 7.4 ms, TE = 3 ms, TI = 600 ms, 10° flip angle, 25.6 cm field of view, matrix = 256 × 256. The voxel dimensions were 1 × 1 × 1 mm. Images were realigned using the line between the anterior and posterior commissures and the sagittal sulcus to correct for head tilt.

### 2.2.2. Image processing and automated parcellation

The MRI scans were analyzed using the FreeSurfer software package (version 3.0.5) (Dale et al., 1999; Fischl et al., 1999a; Fischl et al., 2004), which is freely available on-line at <http://surfer.nmr.mgh.harvard.edu/>. FreeSurfer has a specialized tool for automated parcellation of the neocortical gray matter. The hallmarks of the process are the computation of the curvature of the gray and white matter interface in order to characterize the sulci and gyri, and inflation of the whole brain into a sphere for the purpose of registering subjects to the standard atlas (Desikan et al., 2006; Fischl and Dale, 2000; Fischl et al., 2001; Fischl et al., 1999b; Fischl et al.,

2004). Mapping between subjects and the atlas is performed using a non-rigid registration on the inflated surface. The end result is the parcellation of the human cortex into 34 regions of interest in each hemisphere (Desikan et al., 2006). The parcellation for rostral and caudal middle frontal gyri (Fig. 2A) was visually inspected, compared to the parcellation method as suggested by Crespo-Facorro et al. (1999), and no correction was needed. The FreeSurfer automated parcellation method has been cross-validated in healthy and diseased subjects (Desikan et al., 2006) and applied successfully in schizophrenia subjects (Venkatasubramanian et al., 2008).

### 2.2.3. Delineation of MR-MFG

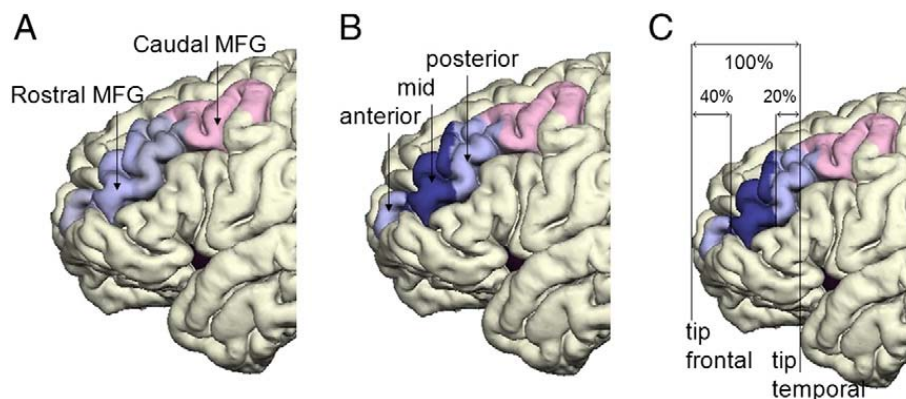
Rostral MFG was further subdivided into anterior, mid and posterior portions (see Fig. 2B); the MR-MFG was the region of main interest. Localization rules for MR-MFG were based on cytoarchitectonic data of the BA46 between the anterior and posterior Talairach coordinates +50 and +29 (Rajkowska and Goldman-Rakic, 1995), and implemented as proportional divisions (40%, 40%, and 20%) of the distance between the tip of the temporal and frontal lobe to account for size variability in the human brain (Fig. 2C). The middle part of those divisions corresponds to BA46, respectively to MR-MFG. These delineation rules were applied previously in a semi-automatic approach to isolate this area (Al-Hakim et al., 2006). The tip of the lobe was identified as the most anterior coronal plane that just showed gray matter and was expressed in the coordinates of the appropriate coronal planes in each subject. The coordinates were used to determine the percentages of the divisions. The new coordinates were used in the script to cut the label map of rostral MFG and generate the MR-MFG label map. The cortical volumes were calculated using the statistical module of the FreeSurfer software, which integrates the area of each surface triangle and multiplies it by the mean thickness over the entire ROI.

### 2.2.4. Volume normalization

Gray matter volumes were normalized by the combined volumes of the cerebral cortex on the left and right hemisphere, a measure of the neocortical gray matter, which was derived from FreeSurfer.

### 2.2.5. Statistical analysis

Statistical analyzes were performed using the Statistical Package for Social Sciences (SPSS) (version 16.0; SPSS Inc., Chicago, IL, USA). We conducted MANOVA analyses for each region separately with one within factor of side and one between factor of group, and followed with MANOVAs on the sub-regions of rostral MFG in order to characterize precisely the source of the group differences for this region (one within factor of side and one between factor of group). The main effect of side and group for each region are reported, but the side by group interaction was not statistically significant in any model so these results are not reported. We corrected all group comparisons for multiple comparisons using a Bonferroni correction. In particular, for the first stage of analysis, we multiplied the *p*-values by two, based on the regions of interest (rostral and caudal), and for the second stage of analysis, we multiplied the *p*-values by three, based on the



**Fig. 2.** Pial surface reconstruction representing the parcellated subregions of MFG. Panel A shows caudal MFG (colored pink) and rostral MFG (light blue). Panel B shows the three subregions of the rostral MFG: the anterior rostral MFG, mid-rostral MFG (MR-MFG) (dark blue) and posterior rostral MFG. Panel C demonstrates the anterior and posterior boundaries of MR-MFG, adapted from Al-Hakim and colleagues (Al-Hakim et al., 2006).

regions of the rostral MFG (anterior, posterior, and middle sub-regions).

Sociodemographic data, scores on WRAT3, WAIS-III Verbal IQ, and WAIS-III Performance IQ tests were analyzed for group differences using ANOVA.

**3. Results**

**3.1. Subjects**

Patients and controls were group matched on the following variables: age at MRI scan ( $p=0.67$ ), Parental Socioeconomic Status (PSES,  $p=0.54$ ), and handedness score ( $p=0.14$ ). All subjects were male. Additionally, there were no significant group differences in academic abilities as revealed by the WRAT3 score ( $p=0.09$ ), an estimate of premorbid IQ (Table 1). Patients with schizophrenia did, however, show significantly lower current socioeconomic status than normal control subjects (SES,  $p=0.001$ ), lower

scores on WAIS-III Verbal IQ ( $p=0.010$ ) and on WAIS-III Performance IQ ( $p=0.005$ ), as well on years of education ( $p=0.007$ ), which is consistent with impairment resulting from the illness (Table 1) (Weickert et al., 2000).

**3.2. Volume comparison**

Table 2 provides relative volumes of gray matter for MFG and for each of the subregions of MFG in subjects with schizophrenia and healthy controls. The regions and sub-regions are represented in Fig. 2A and B. The MFG is the combined area of rostral and caudal MFG, colored light blue and pink in Fig. 2A. The rostral MFG is further divided into the anterior-rostral MFG, light blue in Fig. 2B, MR-MFG, dark blue, and posterior-rostral MFG, light blue. The delineation of the mid rostral MFG is represented in Fig. 2C. The three regions of highest interest, the MFG, the rostral MFG and MR-MFG, are highlighted in bold in Table 2 as they show statistically significant differences in gray matter volumes between

**Table 1**  
Demographic and clinical characteristics of study groups.

Variable	Schizophrenic patients				Healthy control subjects				Group difference $p$
	Mean	SD	$n$	Range	Mean	SD	$n$	Range	
Age (years)	38.2	9.6	20	22–55	36	11	20	21–55	0.668
Gender	Males				Males				
Handedness <sup>a</sup>	0.70	0.25	20	0.25–1.00	0.80	0.17	20	0.47–1.00	0.140
Socioeconomic status <sup>b</sup>									
Subject's own	3.6	1.1	20		2	0.7	20		0.001**
Parental	2.6	1.2	20		2.3	1.2	19		0.538
Education (school years)	13.2	2	20		15	1.9	20		0.007**
WRAT3 – scaled reading score	96.7	12.4	17		103.8	11.3	18		0.087
WAIS-III Verbal IQ	98.7	16.7	20		114.8	11.3	18		0.10
WAIS-III Performance IQ	91.5	13.1	20		109.6	20.1	11		0.005**
Symptom onset (years)	23.5	5.6	18		NA				
Duration of illness (years)	16.1	10.0	17		NA				
Antipsychotic medication dosage <sup>c</sup>	330	281	20		NA				
PANSS (total score)	85.6	28	20		NA				

WRAT3 = Wide Range Achievement Test 3, scaled score (Wilkinson, 1993); WAIS-III = Wechsler Adult Intelligence Scale–3rd Edition (Wechsler, 1997); IQ = intelligence quotient; PANSS = Positive and Negative Syndrome Scale (Kay et al., 1987); SD = standard deviation,  $n$  = number of participants,  $p$  = significance 2-tailed, NA = data not applicable.

<sup>a</sup> Handedness was evaluated using the Edinburgh inventory and right-handedness is above 0.

<sup>b</sup> Higher scores indicate lower socioeconomic status (Hollingshead, 1965).

<sup>c</sup> Chlorpromazine equivalent (mg).

\*\* Significance of  $p < 0.01$ .

**Table 2**

Gray matter volumes of MFG and its subregions in patients and controls. The gray matter volumes of the MFG, and its subregions, the rostral MFG and the MR-MFG, show significant group differences, whereas the remaining regions do not, indicating that the group differences detected in MFG is solely driven by the MR-MFG region.

Brain region	Descriptive data of relative volume (%)								Group differences
	Schizophrenia group (n = 20)				Healthy control group (n = 20)				
	Left hemisphere		Right hemisphere		Left hemisphere		Right hemisphere		
	Mean	SD	Mean	SD	Mean	SD	Mean	SD	
MFG	3.315	0.277	3.599	0.246	3.570	0.352	3.787	0.303	p < 0.008
Caudal MFG	1.403	0.176	1.311	0.136	1.461	0.180	1.360	0.176	ns
Rostral MFG	1.911	0.169	2.288	0.183	2.108	0.296	2.426	0.224	p < 0.014
Anterior-rostral MFG	0.237	0.127	0.360	0.141	0.232	0.088	0.301	0.079	ns
Mid-rostral MFG (MR-MFG)	0.785	0.142	0.883	0.120	0.911	0.186	1.005	0.127	p < 0.012
Posterior-rostral MFG	0.652	0.255	0.772	0.200	0.715	0.281	0.842	0.224	ns

MFG = Middle Frontal Gyrus, ns = non-significant, p = significance 2-tailed, SD = standard deviation.

schizophrenia and healthy subjects. Fig. 3 shows scatterplots of those three regions, the relative volumes of MFG, rostral MFG and MR-MFG for both hemispheres in schizophrenia and healthy subjects.

The initial MANOVA analyses suggested a significant group difference in the rostral [ $F(1, 38) = 8.27$ ,  $p < 0.007 \times 2 = 0.014$ ] but not caudal MFG [ $F(1, 38) = 1.67$ ,  $p < 0.205 \times 2 = 0.41$ ]. The follow-up MANOVAs on the rostral region pointed to the mid-rostral region as the brain region driving the group difference: anterior rostral MFG: [ $F(1, 38) = 1.12$ ,  $p < 0.297 \times 2 = 0.594$ ]; mid-rostral MFG: [ $F(1, 38) = 9.69$ ,  $p < 0.004 \times 2 = 0.008$ ]; post-rostral MFG: [ $F(1, 38) = 0.99$ ,  $p < 0.326 \times 2 = 0.652$ ]. For all regions and in both groups the left side was smaller than the right side: rostral MFG [ $F(1, 38) = 75.64$ ,  $p < 0.001$ ]; caudal MFG [ $F(1, 38) = 8.87$ ,  $p < 0.005$ ].

Thus, to summarize, the gray matter volumetric differences in MFG were driven by the MR-MFG and none of the other subregions. In the MR-MFG region, schizophrenic subjects, relative to controls, evinced reduced cortical gray matter.

#### 4. Discussion

It was our goal to use morphometric images to delineate a part of the MFG where substantial overlap of BA46 maps was previously observed and to explore differences in gray matter volume of this region between the schizophrenia and the control group.

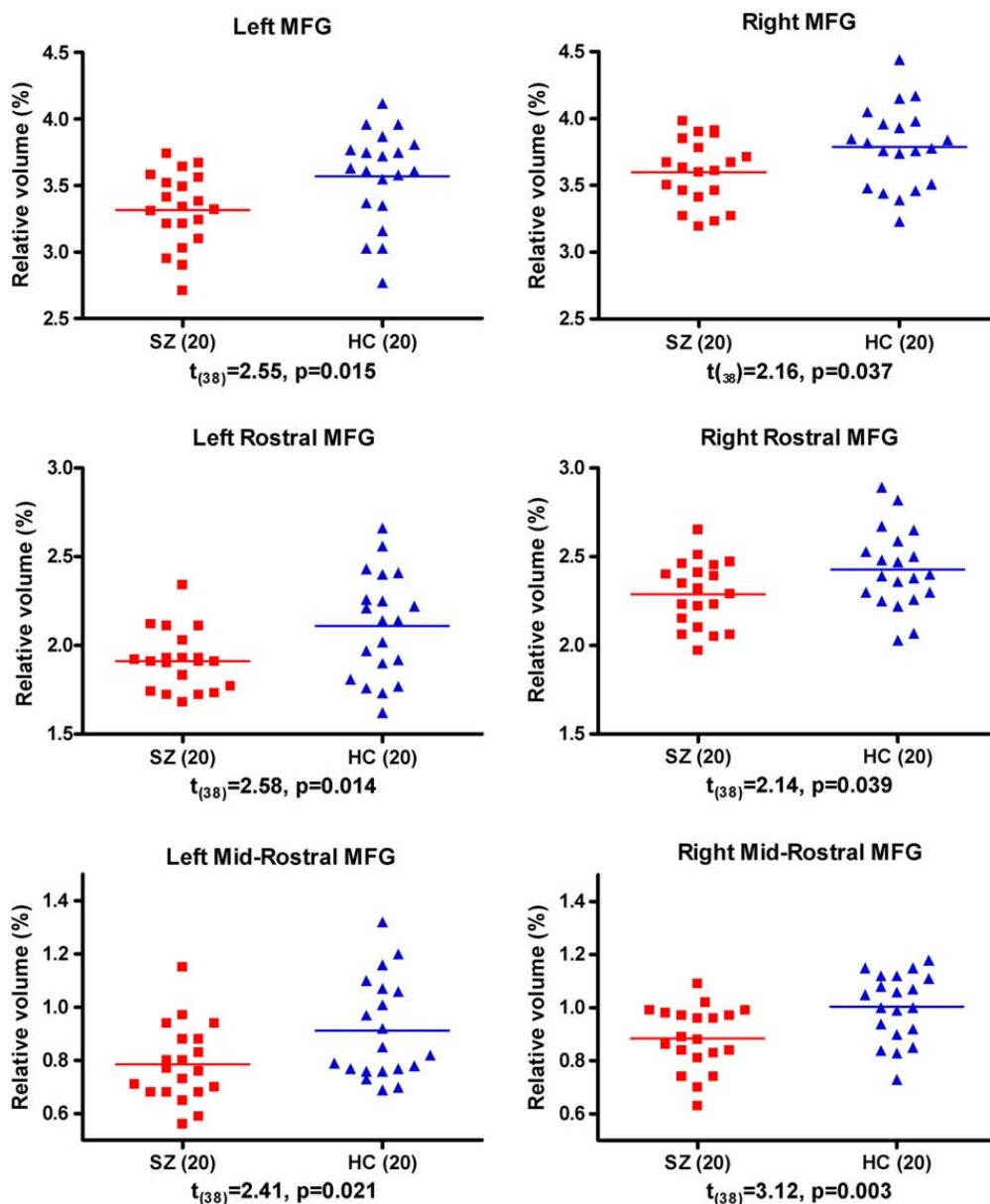
DLPFC has been explored widely as it is believed to be one of the sites of working memory. The definition of DLPFC varies in the extent of the region depending on the study. Some studies consider MFG and SFG to be part of the DLPFC and some vary in the anterior or posterior extension of the gyri (Gur et al., 2000; Tisserand et al., 2002). Due to the inconsistent definition of DLPFC we have concentrated on the MFG, where PET and fMRI have demonstrated working memory deficits in schizophrenia patients (e.g., Cannon et al., 2005; Glahn et al., 2005; Perlstein et al., 2001; Weinberger et al., 1986) and in unaffected relatives (Meda et al., 2008), and where BA46, a region that has been shown to be involved in

memory in experiments in primates, is located (Goldman-Rakic, 1987).

Several morphometric studies have investigated MFG. A meta-analysis of 31 peer-reviewed voxel-based-morphometry studies with a total of 1195 patients with schizophrenia and 1162 healthy controls showed gray matter density reduction in the left MFG in patients with schizophrenia (Glahn et al., 2008). Cortical thinning of MFG has also been reported to be bilateral in schizophrenia patients (Kuperberg et al., 2003; Nesvag et al., 2008). Moreover, studies using manual delineation as a method report reduced gray matter volume in MFG in schizophrenia subjects (Goldstein et al., 1999; Gur et al., 2000; Kasperek et al., 2007; Thompson et al., 2001), as well as reduction in right MFG (Gaser et al., 1999). Goldstein et al. reported 10% reduction in patients with schizophrenia compared with healthy controls, which confirms the magnitude of changes we have measured, namely a reduction of gray matter volume in the MFG of about 8% in the left and 5% in the right hemisphere in the schizophrenia group. In summary, morphometric studies suggest gray matter volume reductions in the MFG in patients with schizophrenia, but have not explored whether the whole or just a part of this region is contributing. Our study narrows this finding specifically to mid-rostral MFG.

The only study, to our knowledge, to explore the rostral part of MFG in schizophrenia subjects is the work by Zuffante et al. (2001), who also evaluated BA46, as defined by Rajkowska and Goldman-Rakic (1995). These investigators delineated this area by manually drawing on coronal slices. They did not find any changes in the gray matter volumes between patients and controls. The discrepancy between findings from the Zuffante study and findings from the current study are likely due to the fact that they were not able to include the anterior portion of BA46.

It might be surprising that we have devoted our study to a single and small area in the prefrontal lobe, when the current trend in exploration of the etiology of schizophrenia is to investigate the connectivity between brain regions. We note, however, that DLPFC is currently too loosely defined and too large to investigate connections to other brain regions involved in working memory. Therefore we focused on delineating a small region within the DLPFC that we believe



**Fig. 3.** Volume comparison of MFG and its subregions. Relative volume = [Absolute volume (cm<sup>3</sup>)/Cortex volume (cm<sup>3</sup>)] × 100 (%). Bars indicate the means. Probabilities are from independent-sample *t*-tests. Abbreviations: MFG = middle frontal gyrus; HC = healthy controls; SZ = schizophrenia subjects.

is likely important in schizophrenia and will be most meaningful for future studies investigating connectivity abnormalities in the brain in schizophrenia.

One limitation of the study lies in the resolution of the MRI and the partial delineation of the whole BA46. Cytoarchitectonic studies show that the extensions of BA46 vary across subjects and across gyri (Rajkowska and Goldman-Rakic, 1995). Nevertheless, Rajkowska and Goldman-Rakic were able to identify a major region of overlap between subjects for BA46. We focused on this region of overlap because structural MRI currently does not provide the resolution to visualize cytoarchitectonically related regions. In order to delineate further the whole area of BA46, it might be necessary to combine data from fMRI and structural MRI and to delineate the region in each subject individually.

In this study we successfully applied FreeSurfer, a software program based on 3-dimensional views of reconstructed brain surfaces. Using this method we showed volumetric differ-

ences between the chronic schizophrenia and the control group that were accounted for by differences in gray matter volume located exclusively in the MR-MFG, and none of the other subregions of MFG. This finding is important as the MR-MFG corresponds to BA46, a region reported to be involved in working memory.

**Role of funding source**

The funding source had no role in study design; the collection, analysis nor interpretation of data; writing of the paper; nor in the decision for publication.

**Contributors**

Z. Kikinis, J.H. Fallon, P. Nestor, R.W. McCarley, R. Kikinis, M. Kubicki, M.E. Shenton designed the study and wrote the protocol. C. Davidson, L. Bobrow P. Pelavin preprocessed the images. B. Fischl and A. Yendiki advised on application of FreeSurfer software and scripts. M. Niznikiewicz undertook the statistical analysis. Z. Kikinis wrote the draft of the manuscript. All authors contributed and have approved the final manuscript.

**Conflict of interest**

All authors have no conflict of interest to this report.

**Acknowledgements**

This work was supported, in part, by a NARSAD Young Investigator Award (ZK), by the Department of Veterans Affairs Merit Awards (MES, RWM), by a VA Schizophrenia Center (RWM, MES), by grants from the National Institute of Mental Health including a Career Reentry Supplement (ZK) on R01 MH 50747 (MES), a K05 MH 070047 (MES), an R01 MH 40799 and R01 MH 052807 (RWM), and a NIH Mental Health Centers for Interventional Development and Applied Research-CIDAR – P50 MH 080272 (RWM, also MES, MK), and, finally, by grants from the National Alliance for Medical Image Computing (NAMIC – U54 EB005149 (RK, also MK, MES), NCIGT P41 RR 019703 (RK) and a Neuroimage Analysis Center (NAC) P41 RR 13218 (RK). The authors gratefully acknowledge the support of Francisco Romo, M.D. and Brain Healy, PhD, for his assistance on the statistical analyses.

**References**

- Al-Hakim, R., Fallon, J.H., Nain, D., Melonakos, J., Tannebaum, A., 2006. A dorsolateral prefrontal cortex semi-automatic segmenter. *Proc. SPIE* 6144, 170–177.
- Bartley, A.J., Jones, D.W., Weinberger, D.R., 1997. Genetic variability of human brain size and cortical gyral patterns. *Brain* 120 (Pt 2), 257–269.
- Brodmann, K., 1909. Vergleichende Lokalisationslehre der Grosshirnrinde in ihren Prinzipien dargestellt auf Grund des Zellenbaues. Barth, Leipzig.
- Buchanan, R.W., Vladar, K., Barta, P.E., Pearlson, G.D., 1998. Structural evaluation of the prefrontal cortex in schizophrenia. *Am. J. Psychiatry* 155, 1049–1055.
- Cannon, T.D., Glahn, D.C., Kim, J., Van Erp, T.G., Karlsgodt, K., Cohen, M.S., Nuechterlein, K.H., Bava, S., Shirinyan, D., 2005. Dorsolateral prefrontal cortex activity during maintenance and manipulation of information in working memory in patients with schizophrenia. *Arch. Gen. Psychiatry* 62, 1071–1080.
- Crespo-Facorro, B., Kim, J.J., Andreasen, N.C., O'Leary, D.S., Wiser, A.K., Bailey, J.M., Harris, G., Magnotta, V.A., 1999. Human frontal cortex: an MRI-based parcellation method. *Neuroimage* 10, 500–519.
- Dalby, J.T., Williams, R., 1986. Preserved reading and spelling ability in psychotic disorders. *Psychol. Med.* 16, 171–175.
- Dale, A.M., Fischl, B., Sereno, M.I., 1999. Cortical surface-based analysis. I. Segmentation and surface reconstruction. *Neuroimage* 9, 179–194.
- Desikan, R.S., Segonne, F., Fischl, B., Quinn, B.T., Dickerson, B.C., Blacker, D., Buckner, R.L., Dale, A.M., Maguire, R.P., Hyman, B.T., Albert, M.S., Killiany, R.J., 2006. An automated labeling system for subdividing the human cerebral cortex on MRI scans into gyral based regions of interest. *Neuroimage* 31, 968–980.
- Fischl, B., Dale, A.M., 2000. Measuring the thickness of the human cerebral cortex from magnetic resonance images. *Proc. Natl Acad. Sci. USA* 97, 11050–11055.
- Fischl, B., Sereno, M.I., Dale, A.M., 1999a. Cortical surface-based analysis. II: inflation, flattening, and a surface-based coordinate system. *Neuroimage* 9, 195–207.
- Fischl, B., Sereno, M.I., Tootell, R.B., Dale, A.M., 1999b. High-resolution intersubject averaging and a coordinate system for the cortical surface. *Hum. Brain Mapp.* 8, 272–284.
- Fischl, B., Liu, A., Dale, A.M., 2001. Automated manifold surgery: constructing geometrically accurate and topologically correct models of the human cerebral cortex. *IEEE Trans. Med. Imaging* 20, 70–80.
- Fischl, B., van der Kouwe, A., Destrieux, C., Halgren, E., Segonne, F., Salat, D.H., Busa, E., Seidman, L.J., Goldstein, J., Kennedy, D., Caviness, V., Makris, N., Rosen, B., Dale, A.M., 2004. Automatically parcellating the human cerebral cortex. *Cereb. Cortex* 14, 11–22.
- Gaser, C., Volz, H.P., Kiebel, S., Riehemann, S., Sauer, H., 1999. Detecting structural changes in whole brain based on nonlinear deformations—application to schizophrenia research. *Neuroimage* 10, 107–113.
- Glahn, D.C., Ragland, J.D., Abramoff, A., Barrett, J., Laird, A.R., Bearden, C.E., Velligan, D.I., 2005. Beyond hypofrontality: a quantitative meta-analysis of functional neuroimaging studies of working memory in schizophrenia. *Hum. Brain Mapp.* 25, 60–69.
- Glahn, D.C., Laird, A.R., Ellison-Wright, I., Thelen, S.M., Robinson, J.L., Lancaster, J.L., Bullmore, E., Fox, P.T., 2008. Meta-analysis of gray matter anomalies in schizophrenia: application of anatomic likelihood estimation and network analysis. *Biol. Psychiatry* 64, 774–781.
- Goldman-Rakic, P.S., 1987. Circuitry of primate prefrontal cortex and regulation of behaviour by representational memory. In: Brooks, B. (Ed.), *Handbook of Physiology, the Nervous System V*.
- Goldstein, J.M., Goodman, J.M., Seidman, L.J., Kennedy, D.N., Makris, N., Lee, H., Tourville, J., Caviness Jr., V.S., Faraone, S.V., Tsuang, M.T., 1999. Cortical abnormalities in schizophrenia identified by structural magnetic resonance imaging. *Arch. Gen. Psychiatry* 56, 537–547.
- Gur, R.E., Cowell, P.E., Latshaw, A., Turetsky, B.L., Grossman, R.I., Arnold, S.E., Bilker, W.B., Gur, R.C., 2000. Reduced dorsal and orbital prefrontal gray matter volumes in schizophrenia. *Arch. Gen. Psychiatry* 57, 761–768.
- Hollingshead, A., 1965. Two Factor Index of Social Position. Yale University Press, New Haven, CT.
- Kasperek, T., Prikryl, R., Mikl, M., Schwarz, D., Ceskova, E., Krupa, P., 2007. Prefrontal but not temporal grey matter changes in males with first-episode schizophrenia. *Prog. Neuropsychopharmacol. Biol. Psychiatry* 31, 151–157.
- Kay, S.R., Fiszbein, A., Opler, L.A., 1987. The positive and negative syndrome scale (PANSS) for schizophrenia. *Schizophr. Bull.* 13, 261–276.
- Kuperberg, G.R., Broome, M.R., McGuire, P.K., David, A.S., Eddy, M., Ozawa, F., Goff, D., West, W.C., Williams, S.C., van der Kouwe, A.J., Salat, D.H., Dale, A.M., Fischl, B., 2003. Regionally localized thinning of the cerebral cortex in schizophrenia. *Arch. Gen. Psychiatry* 60, 878–888.
- Meda, S.A., Bhattarai, M., Morris, N.A., Astur, R.S., Calhoun, V.D., Mathalon, D. H., Kiehl, K.A., Pearlson, G.D., 2008. An fMRI study of working memory in first-degree unaffected relatives of schizophrenia patients. *Schizophr. Res.* 104, 85–95.
- Nesvag, R., Lawyer, G., Varnas, K., Fjell, A.M., Walhovd, K.B., Frigessi, A., Jonsson, E.G., Agartz, I., 2008. Regional thinning of the cerebral cortex in schizophrenia: effects of diagnosis, age and antipsychotic medication. *Schizophr. Res.* 98, 16–28.
- Noga, J.T., Bartley, A.J., Jones, D.W., Torrey, E.F., Weinberger, D.R., 1996. Cortical gyral anatomy and gross brain dimensions in monozygotic twins discordant for schizophrenia. *Schizophr. Res.* 22, 27–40.
- Perlstein, W.M., Carter, C.S., Noll, D.C., Cohen, J.D., 2001. Relation of prefrontal cortex dysfunction to working memory and symptoms in schizophrenia. *Am. J. Psychiatry* 158, 1105–1113.
- Petrides, M., Alivisatos, B., Evans, A.C., Meyer, E., 1993. Dissociation of human mid-dorsolateral from posterior dorsolateral frontal cortex in memory processing. *Proc. Natl Acad. Sci. USA* 90, 873–877.
- Rajkowska, G., Goldman-Rakic, P.S., 1995. Cytoarchitectonic definition of prefrontal areas in the normal human cortex: II. Variability in locations of areas 9 and 46 and relationship to the Talairach Coordinate System. *Cereb. Cortex* 5, 323–337.
- Spitzer, R., Williams, J.B.W., Gibbon, M., First, M. (Eds.), 1990a. The Structured Clinical Interview for DSM-III-R-non-patient Edition (SCID-NP). American Psychiatric Association, Washington, DC.
- Spitzer, R., Williams, J.B.W., Gibbon, M., First, M. (Eds.), 1990b. The Structured Clinical Interview for DSM-III-R (SCID). American Psychiatric Association, Washington, DC.
- Thompson, P.M., Vidal, C., Giedd, J.N., Gochman, P., Blumenthal, J., Nicolson, R., Toga, A.W., Rapoport, J.L., 2001. Mapping adolescent brain change reveals dynamic wave of accelerated gray matter loss in very early-onset schizophrenia. *Proc. Natl Acad. Sci. USA* 98, 11650–11655.
- Tisserand, D.J., Pruessner, J.C., Sanz Arigita, E.J., van Boxtel, M.P., Evans, A.C., Jolles, J., Uylings, H.B., 2002. Regional frontal cortical volumes decrease differentially in aging: an MRI study to compare volumetric approaches and voxel-based morphometry. *Neuroimage* 17, 657–669.
- Venkatasubramanian, G., Jayakumar, P.N., Gangadhar, B.N., Keshavan, M.S., 2008. Automated MRI parcellation study of regional volume and thickness of prefrontal cortex (PFC) in antipsychotic-naive schizophrenia. *Acta Psychiatr. Scand.* 117, 420–431.
- Wechsler, D., 1997. Wechsler Memory Scale-Third Edition. The Psychological Corporation. Harcourt Brace & Company, San Antonio Texas.
- Weickert, T.W., Goldberg, T.E., Gold, J.M., Bigelow, L.B., Egan, M.F., Weinberger, D.R., 2000. Cognitive impairments in patients with schizophrenia displaying preserved and compromised intellect. *Arch. Gen. Psychiatry* 57, 907–913.
- Weinberger, D.R., Berman, K.F., Zec, R.F., 1986. Physiologic dysfunction of dorsolateral prefrontal cortex in schizophrenia. I. Regional cerebral blood flow evidence. *Arch. Gen. Psychiatry* 43, 114–124.
- Wible, C.G., Shenton, M.E., Fischer, I.A., Allard, J.E., Kikinis, R., Jolesz, F.A., Iosifescu, D.V., McCarley, R.W., 1997. Parcellation of the human prefrontal cortex using MRI. *Psychiatry Res.* 76, 29–40.
- Wilkinson, G.S., 1993. Wide Range Achievement Test Administration Manual. Wide Range, Inc, 15 Ashley Place, Suite 1A., Wilmington, DE.
- Zuffante, P., Leonard, C.M., Kuldau, J.M., Bauer, R.M., Doty, E.G., Bilder, R.M., 2001. Working memory deficits in schizophrenia are not necessarily specific or associated with MRI-based estimates of area 46 volumes. *Psychiatry Res.* 108, 187–209.